



FUE Megasections - Evolution of a Technique

Robert M. Bernstein, M.D., William R. Rassman, M.D.

The ability to complete the hair restoration process in just a few sessions had long been an elusive goal for patients seeing treatment for their hair loss. This goal was eventually achieved with extensive micrografting¹ and then with the more refined technique of Follicular Unit Transplantation.² The natural evolution is to be able to accomplish this task with Follicular Unit Extraction.³ This time has arrived!

The purpose of this writing is to identify the special organizational and technical skills required for FUE Megasections, describe its advantage over other FUE techniques and to discuss some of the long-term implications of FUE, particularly with respect to the effects of FUE on the donor scalp.

The Fox Test

In spite of significant improvements in techniques over the past several years, we still believe that each patient is different enough, with respect to the ease of extraction, that testing prior to the actual FUE procedure is warranted. This may not be necessary when treating triangular alopecia, restoring eyebrows, adding hair to donor scars, or in other cases where there is a limited demand for hair. However, in situations where the long-term demand for hair is large, performing a Fox Test is important for long-term planning. We particularly stress "long-term" for this information is probably more important in treating early recession in a person in their late twenties, than it is for the Norwood Class 6 patient in his late fifties.

In the latter case, if extraction proves to be difficult, (i.e. the grafts shred or fragment on extraction) the yield may be lower than expected or the procedure may take longer than anticipated. In the worse case, a strip incision can be used to achieve the desired number of follicular units. However, in the younger person who plans on wearing his hair very short on the sides, having to abort FUE is a disaster, since this patient may have opted out of the hair restoration process altogether, if he had know in advance he were a poor candidate for the procedure.

To make matters more complicated, Fox Testing (Follicular Unit Extraction) is not black and white. It varies from patient to patient and can decrease in the same patient over time (as the same areas are accessed more than once). We use a subjective scale of 1 to 5 for the assessment, assigning a score of 1 (now accounting for over 90% of patients) when intact follicular units literally pop out of the scalp or when there is only occasional transection of individual hairs in the unit. For Fox grade 2 patients, extraction may be relatively easy in the first session, but in subsequent procedures (when the donor area is slightly scarred) it becomes more problematic and the yield starts to decline. In these patients, the long-term yield can be compromised and planning extremely difficult. With Fox grade 3 to 5 patients, where large numbers of grafts are needed, the yield is too low for the FUE procedure to be successful. Here the decision not to use FUE is straight forward. Unfortunately, the physician cannot make this decision without prior knowledge of the Fox results. As a consequence, the patient may have inadvertently been started on a course of treatment that cannot be completed.

Factors in transitioning from 500-600 graft cases into FUE Megasections

For this discussion, we arbitrarily define a FUE Megasection as a single session of 1,500 or more FU grafts, cognizant of the fact that traditional transplant sessions were first called "megasections" when they exceeded 1000 grafts. The bar, of course was soon raised to 1500 and then 2000 grafts as skills improved, with sessions greater than 2,500 now being routine in some clinics.

The key to successful FUE Megasections is the economy of movement during the extraction process. At the "micro" level this demands:

- Excellent lighting.
- Adequate magnification for the surgeon and staff.
- Determining the angle of the hair below the surface of the skin. In almost all instances, the angle of the emergent hair is more acute than the angle of follicle in the dermis. The incision must obviously anticipate this and be oriented in the direction of the follicle rather than the visible hair.
- Using a single, short twisting motion of the punch (<180 degrees) with the hand perfectly stable. We find that clockwise rotation (for the right-handed person) generally provides more stability than twisting in the other direction. A back-and-forth motion causes unnecessary transection and is incompatible with successful FUE, as is a 360 degree rotation of the punch. In some cases of Fox grade 1 cases, direct pressure alone (without any twisting) may be sufficient to extract the grafts.
- Sharp punches. These are critical to minimize the amount of twisting needed to cut into the dermis. In addition, they allow the surgeon to feel the "release" as the punch progresses from tougher dermis into the subcutaneous tissue.

- Punch size of 0.9-1.0mm in diameter. This size is large enough to encompass the width of the follicular unit, yet small enough to minimize wound size and scarring.

At the team organization level this entails:

- Batching the incision (and dissection when necessary) phase of the procedure and separating it from the actual extraction phase. This is a critical aspect in the organization of the procedure. Batching greatly speeds up the process, but doesn't provide immediate feedback to the surgeon with respect to transection.
- It is important, particularly at the beginning of the session, to examine every graft as it is incised and extracted so that adjustments can be made with respect to angling the punch. This is also important as new areas of the scalp are accessed. It is important to note that hair does not always exit from the donor scalp in exactly the same direction, even with adjacent follicular units. The need for constant adjustment of the hair angle is critical to an efficient extraction.
- In cases where the angle is consistent and easy to determine, a surgeon can easily batch up to 50, or more, grafts at a time. However, in more difficult cases, or in more difficult areas of the scalp, checking for transection should be done every few grafts throughout the duration of the procedure. This must also be done if the grafts have any tendency to fall into the fat. These grafts can be extruded by putting pressure on the surrounding skin, or by using jeweler's forceps to pull them out and prevented by making the initial incision more superficial. With batching, however, there is no way to keep track of the grafts that may have inadvertently entered the subcutaneous space. The continuous checking for transection (necessary in all cases that are not Fox 1) and for grafts that may have slipped into the fat, greatly decreases the efficiency of the procedure and increases the operating time.
- Positioning the holding solution close to the area being operated on so that the extracted grafts can be immediately placed into the solution after extraction. This will minimize excess movements and also avoid desiccation of grafts.
- Working with two parallel teams, if practical, for both harvesting and placing.
- Shaving the back and sides of the scalp to 1-mm will provide access to the largest surface to harvesting the grafts. For smaller FUE sessions, clipping horizontal strips of hair allows for an undetectable donor area, but it is impractical for large FUE sessions.

Other issues:

- Microscopic evaluation and, when needed, trimming the grafts of excess tissue. This is particularly important at the frontal hairline to insure that the follicular units used in this location are only single-hair grafts.
- Sorting and recording the follicular unit grafts by the numbers of hairs they contain. This is important so that there will be enough grafts to create a frontal hairline or other areas that require single-hair grafts. There is a tendency to remove only the largest units, resulting in too few 1-hair follicular unit grafts. By giving the physician feedback, smaller units can be extracted to fill this need.
- Tumescence is critical, but it is most effective when injected superficially into the dermis. Normal saline should be injected into the dermal layer in small areas at a time, as the saline diffuses away quickly and the turgid effect is rapidly lost. Tumescence into the subcutaneous space offers little benefit.

Advantages of performing a FUE Megasesion over staged FUE sessions

Various schedules for performing FUE have been devised. These include daily, weekly, and monthly sessions. Daily sessions have the advantage of using post-op edema as a form of built-in tumescence, and aggregating the sessions for patients that travel a distance for the procedure. Weekly sessions have an advantage over monthly sessions in that the latter makes identification of recipient grafts difficult.

However, FUE Megasesions have advantages over both. The single session avoids the post-op crusting (and associated bacterial buildup) from daily sessions that can alter the visual field and it allows for easiest placement of recipient grafts, since all the follicular units are "at hand" when making judgments as to the density and distribution of grafts. In addition, anesthesia does not have to be placed into an edematous recipient area filled with 1-day old grafts that are tenuously anchored, nor do additional sites have to be made. Most importantly, the patient does not have to suffer the inconvenience of daily trips to the operating room. In the future, is it hoped that extraction and implantation can be carried out simultaneously, significantly decreasing the duration of the procedure.

Donor Scarring

Since the main advantage of FUE is the elimination of a linear donor incision, it is ironic that donor scarring is the major limitation to successful Follicular Unit Extraction. Although the individual scars of FUE are small, the cumulative scarring from hundreds to thousands of open wounds, left to heal by secondary intention, is significantly greater than from a linear incision. The small white donor scars may not be visible through normal length hair, but it is disingenuous to represent that scarring doesn't exist. The fine white scarring can be seen if the scalp is clipped or shaved, a style that is increasingly common today.

The major consequence of this scarring is the decreased yield in future FUE sessions. Successful follicular unit extraction depends upon tactile as well as visual cues and scarring in the donor area significantly diminishes the sensitivity of the former. The scars in a previously harvested donor area make it significantly more difficult to extract intact follicular units without transection. The scarring process alters the angle of the follicles, as well as the feel of the dermis. This can be

appreciated both in the vicinity of a linear scar, as well as in the area of previously extracted grafts.

Just as traditional megasections were an improvement over small hair transplant sessions, FUE Megasections offer many advantages over small FUE sessions. However, even with FUE Megasections, the need to go back to the same area for additional grafts in future sessions is not eliminated. The difficulty in extracting intact follicular unit grafts from previously harvested areas may result in decreased overall yield, making subsequent FUE sessions less productive than the first and significantly less robust than traditional strip excision for FUT. This limitation must be discussed with patients and be considered before the first follicular unit extraction session is undertaken.

Case Studies

Patient 1

The patient is a 35 year old male. His goal was to attempt to complete the restoration in a single session and he was absolutely determined not to have it done with strip harvesting. He had average hair weight with good body and white in color. His donor density was 2 hairs/mm² and his Fox Test was classified as 1.

This case is important for a number of technical reasons. The almost clear white hair is very difficult to see, so we dyed his hair black the morning of the surgery. The FOX procedure is very intense so we made sure that there were no interruptions for the day to disturb our concentration. The staff consisted of one surgeon (KWA) and three medical assistants. The procedure took 12 hours to extract and plant 1,901 follicular unit grafts. The grafts were trimmed of excess skin and hair counts were performed. The grafts were sorted in Petri-dishes of cold Ringer's solution and refrigerated at 36 degree Fahrenheit. All of the grafts were removed by the doctor with 91.5% yield of intact units.



Donor area for 1901 grafts one day post-op


Frontal recipient area of approximately 1000 FUs




Crown recipient area of approximately 901 FUs

Patient 2

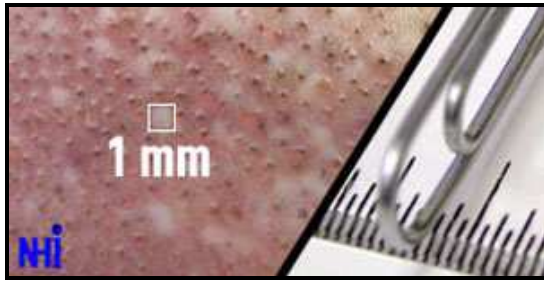
This patient had two FUE procedures 1 and 2 years earlier totaling 1195 grafts. The FUE procedures left small pinhole scars which were hard to see with the hair at a normal length (photo 4). As the hair was clipped very short or shaved (photos 4-5) the scars were visible. Obviously these scars will impact future extraction. In our fairly extensive experience, the scarring shown here is typical for the FUE procedure.



View of FUE donor site one year after surgery (~1600 grafts in two sessions)



Hair clipped view of FUE donor site one year after surgery (~1600 grafts in two sessions)



Head shaved view of FUE donor site one year after surgery (~1600 grafts in two sessions)

References

1. Rassman WR, Carson S. Micrografting in extensive quantities; the ideal hair restoration procedure. *Dermatol Surg* 1995; 21:306-311.
2. Bernstein RM, Rassman WR, Szaniawski W, Halperin A: Follicular Transplantation. *Intl J Aesthetic Restorative Surgery* 1995; 3: 119-32.
3. Rassman WR, Bernstein RM, McClellan R, Jones R, et al. Follicular Unit Extraction: Minimally invasive surgery for hair transplantation. *Dermatol Surg* 2002; 28(8): 720-7.

- [Back to Medical Publications](#)